

## Histopathology quiz

D.N.U. Jayatunge<sup>1</sup>, S.M. Fernandopulle<sup>2</sup>

1. Department of Pathology, Faculty of Medicine, University of Kelaniya

2. Department of Pathology, North Colombo Teaching Hospital

### Case history

A 23-year-old man presented with a painful lump at the ankle. The lump was at the lateral aspect just above the right ankle joint measuring 2cm in maximum dimension. Fine Needle Aspiration Cytology (FNAC) was performed with only a single aspirate since, the procedure was extremely painful for the patient. Blood mixed material was aspirated.

Photomicrographs of the FNAC cytology are given below.

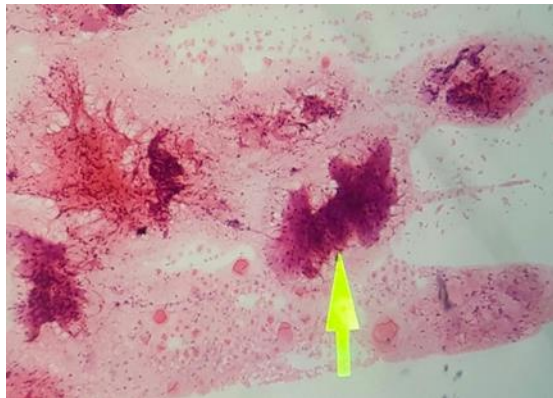


Figure 1: H&E x 40

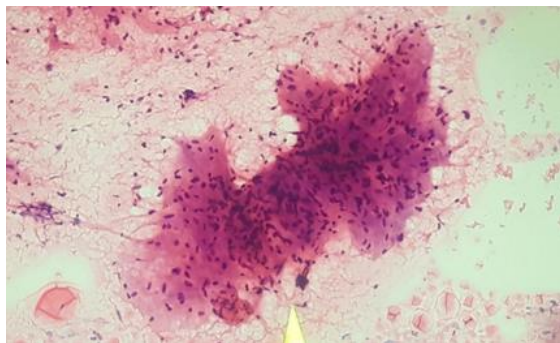


Figure 2: H&E x100

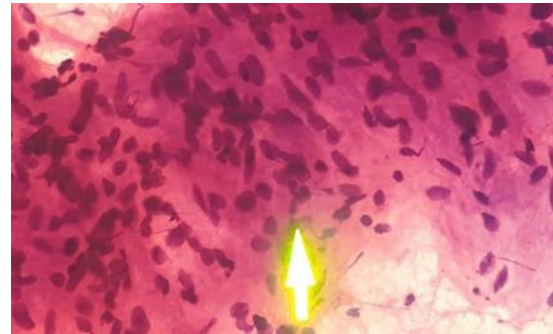


Figure 3: H&E x400

1. How would you classify this lesion? (Benign, intermediate/uncertain behavior or malignant)
2. What is the most likely lineage of this lesion?

(Skeletal muscle, smooth muscle, fibroblast/myofibroblast, nerve sheath, neural)

3. What is your diagnosis/ differential diagnosis?

See page 25-27 for the answer to quiz and discussion.