
The pathology of bronchial and pleural biopsies of patients presenting to a tertiary chest clinic in Sri Lanka

M M A Jayawickrama¹, M D S Lokuhetty², A K C P Amarasinghe³, M J Fernando¹.

Abstract

Introduction: Respiratory diseases are the second leading cause of hospitalization and is a significant cause of morbidity and mortality in Sri Lanka.

Objective: To describe the pathology of bronchial and pleural biopsies in patients referred to a tertiary chest clinic in Sri Lanka.

Method: This retrospective study included 127 patients subjected to bronchial or pleural biopsy at the Chest Clinic Kalutara, from January 1998 to April 2000. Histology slides were reviewed at a conference microscope. The clinical details were obtained from the clinic files.

Results: There were 101 bronchial and 26 pleural biopsies. Twenty five (19.7%) had neoplasms, all seen in bronchial biopsies. These comprised 11 squamous, 8 adeno, 5 poorly differentiated non-small cell and one adenoidcystic carcinoma. Of the non-neoplastic group 20 (15.7%) had pneumonia and its complications. Eighteen (14.2%) had biopsy confirmed tuberculosis, of these 14 were in pleural biopsies and 4 in bronchial biopsies. Other lesions included fibrosis with chronic inflammation 4 (3.1%), interstitial fibrosis 4 (3.1%), fungal infections 3 (2.4%) and chronic inflammation 16 (12.6%). Twenty (15.7%) had non-diagnostic biopsies and normal lung was seen in 17 (13.4%) cases.

Conclusion: Neoplasms were the most commonly encountered lesion in our study. However non-neoplastic conditions were also an important cause of morbidity in this group of patients.

Introduction

Respiratory diseases are the second leading cause of hospitalization in Sri Lanka and are a significant cause of morbidity in the community due to loss of working hours and the impact of chronic respiratory disease on the quality of life. It is the seventh leading cause of hospital deaths (9 per 100,000) among adults and the third leading cause of deaths among children of 1-4 year age group (13 per 100,000) (1).

The aim of this study is to determine disease patterns encountered in bronchial and pleural biopsies of patients presenting to a tertiary chest clinic in Sri Lanka.

Method

This retrospective study included 127 patients subjected to bronchial biopsy using the flexible fiberoptic bronchoscope or needle biopsy of the pleura at the chest clinic and ward of the General Hospital Kalutara from January 1998 to April 2000. Histopathology and cytology slides were reviewed at a conference microscope and the pathology was categorized as neoplastic, pneumonia and its complication, tuberculosis, chronic inflammation, fibrosis with chronic inflammation, fungal infections, interstitial fibrosis, normal histology and non diagnostic. Details of other investigations done were obtained from the clinic files.

1. General Hospital Kalutar

2. Faculty of Medicine, University of Colombo

3. Cancer Institute, Maharagama.

Correspondance: Dr. M.M.A. Jayawickrama, 220 Park Road, Colombo 5, Tel; 508091

Results

There were 101 bronchial biopsies and 26 pleural biopsies of 127 patients. Neoplasms were seen in 25 patients (19.7%). Pneumonia and its complications were seen in 20 patients (15.7%), Tuberculosis 18 (14.2%), chronic inflammation in 16 (12.6%), fibrosis with chronic inflammation in 4 (3.1%), fungal infection in 3 (2.4%), interstitial fibrosis in 4 (3.1%). The biopsy was non-diagnostic in 20 (15.7%) and normal lung histology was seen in 17 (13.4%) biopsies. Neoplasms were encountered only in bronchial biopsies. The histology type, age range, sex distribution and cytology of bronchial wash and brush in biopsies of this group are shown in Table 1. Of the 18 patients (14.8%) with tuberculosis 14 were in pleural biopsies. The chest X rays of these patients showed a unilateral pleural effusion with equal distribution on the left and right side. Four cases of tuberculosis was diagnosed on bronchial biopsy and the X rays of all these patients showed bilateral milliary mottling.

In the patients with pneumonia 45% had resolving pneumonia, 30% had unresolved pneumonia with abscess formation, 20% had interstitial pneumonia and 5% had lung abscess formation.

Of the three cases of fungal infections, Aspergilloma was seen in two cases showing branched hyphae at acute angles (Figure 1) staining positive with periodic acid shift (PAS) stain. The other case showed rounded spores staining positive with Grocotts stain.

The biopsy material was non-diagnostic in 18 (14.3%) of patients. Of these the tissue sampled was insufficient for diagnosis in 72.3%, there was absence of tissue after processing in 11.1%, only a blood clot was seen in 11.1% and degenerated tissue was seen in 5.5%.

Discussion

Neoplasms were the most commonly diagnosed lesions in the bronchial biopsy of patients presenting to this tertiary chest clinic. These patients were referred from medical wards and other nearby hospitals. Eighty percent of these patients were male and they all gave a history of cigarette smoking (2). At the time of bronchoscopy bronchial wash and brush samples were taken for cytology and showed malignant cells in 80 % of patients.

Of the non-neoplastic lesions, the common pathological entities included tuberculosis and chronic inflammation. Most patients with tuberculosis had a pleural effusion and pleural biopsy was helpful in confirming the diagnosis.

With the emergence of new organisms and development of drug resistance by bacteria and mycobacteria showing adaptation to the environment (3, 4) and increased susceptibility to infections in the acquired immune deficient (AIDS) population tuberculosis imposes a major problem in respiratory diseases (5, 6) with global dissemination of mycobacterium tuberculosis (7). There were 8000 new cases of tuberculosis diagnosed in Sri Lanka in the year 2000 of which 80% were pulmonary tuberculosis (8).

Table 1- The histology type ,age range distribution and cytopathology of bronchial wash and brush samples of neoplastic lesions (n=25)

Histology	No	%	Age Range	Sex		Malignant cells	
				M	F	+	-
Squamous Ca	11	44%	51 - 78 yrs	9	2	9	2
Adeno Ca	8	32%	29 - 72 yrs	5	3	6	2
Poorly differentiated Ca	5	20%	50 - 76 yrs	5	-	4	1
Adenoid cystic Ca (Figure 2)	1	4%	44 yrs	1	-	1	-

Ca - carcinoma, Cyto - cytology, M - male, F- female

Partial treatment of pneumonia either due to inadequate dose, duration or insensitive antibiotics results in unresolved pneumonia with resultant complications like lung abscess and empyema. Approximately sixteen percent of patients in our study showed pneumonia and its resultant complications. The biopsy material was non-diagnostic in 13.4% of patients. The biopsy size being too small for conclusive diagnosis and the absence of issue after processing is a common problem in bronchoscopic biopsies.

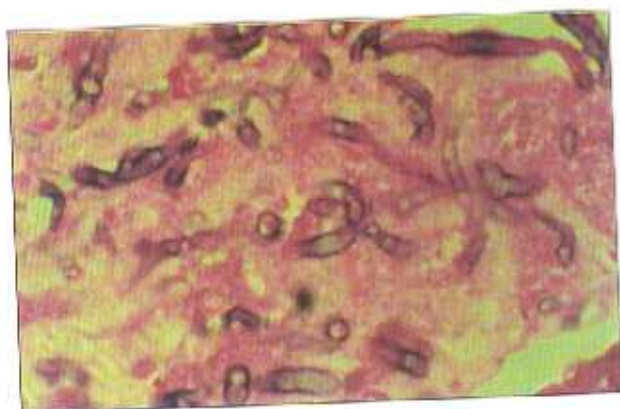


Figure 1 - Aspergilloma of lung showing branched hyphae (H & E 400)

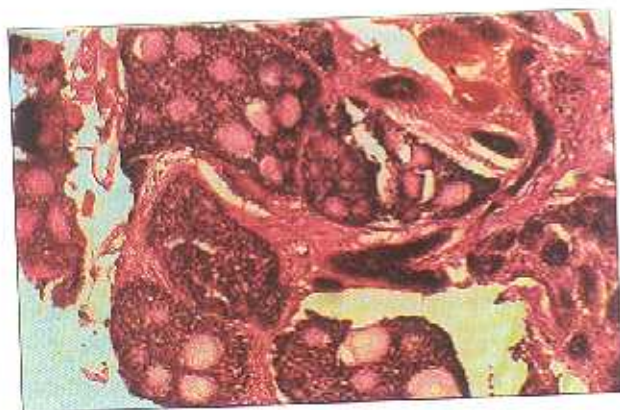

Figure 2 - Adenoid cystic carcinoma of the lung (H & E 200)

Acknowledgments

We thank Dr. Ruchira Fernando, Consultant Histopathologist, NHSL, Colombo and the doctors and staff of the chest clinic, Kalutara for their assistance.

References

1. Annual Health Bulletin, 1995: Ministry of Health, Sri Lanka.
2. Nagomoto N, Saito Y, Imani T, Suda N, Takashashi S, Usuda K et al. Histogenesis and characterization of bronchial carcinoma observed in heavy smokers. *Experimental medicine* 1987;183:265 - 284.
3. Honer K, Bentrap Z, Russell DG. Mycobacterial persistence: adaptation to a changing environment. *Trends in microbiology*, 2001;9:597 - 605.
4. Zahrk TC. Molecular mechanisms regulating persistent mycobacterium tuberculosis infection. *Microbes and infection* 2002;5:159 - 67.
5. Gerd F, Henri T, Philippe L, Achim S, Richard W. The return of tuberculosis. *Diagnostic Microbiology and Infectious Diseases*, 1999;34: 139 - 146 .
6. Michael S, Glickman W, Jacobs Jr R. Microbial Pathogenesis of Mycobacterium tuberculosis. *Cell* 2001;104: 477 - 485.
7. Pablo J B, Barun M, Nataktia E, Kurepina, Barry N, Kreiswirth. Global dissemination of Mycobacterium tuberculosis W - Beijing family strain. *Trends in Microbiology* 2002;10:45 - 52.
8. Annual Health Bulletin 2001, Ministry of Health, Sri Lanka.